

**CHEST WALL ASPERGILLOSIS: AN UNCOMMON PRESENTATION**Supriya Adiody<sup>1</sup>, V. P. Gopinathan<sup>2</sup><sup>1</sup>Professor and HOD, Department of Pulmonary Medicine, Jubilee Mission Medical College, Thrissur, Kerala.<sup>2</sup>Senior Consultant Pulmonologist, Mother Hospital, Thrissur.

**ABSTRACT:** Aspergillus can cause a variety of clinical syndromes in the lung including aspergilloma in patients with preexisting cavities, ABPA, chronic necrotizing aspergillosis and invasive aspergillosis. Invasive aspergillosis may cause pulmonary, rhinocerebroorbital, endocardial, mediastinal, renal and rarely chest wall involvement.<sup>1,2</sup> Chest wall involvement usually begins with a focus of lung infection that spreads directly to an adjacent site or thoracic vertebra.<sup>2</sup> An interesting case of invasive aspergillosis with chest wall, parenchymal and pleural involvement is reported here in an competent patient.

**KEYWORDS:** Allergic Bronchopulmonary Aspergillosis (ABPA), Invasive Aspergillosis.

**HOW TO CITE THIS ARTICLE** Supriya Adiody, V. P. Gopinathan. "Chest Wall Aspergillosis: An Uncommon Presentation". Journal of Evolution of Medical and Dental Sciences 2015; Vol. 4, Issue 91, November 12; Page: 15705-15706, DOI: 10.14260/jemds/2015/2263.

**INTRODUCTION:** Male, 46 years, nonsmoker, presented with right sided chest pain. He had a history asthma from childhood for which he was on steroid inhalers and also a history of having taken incomplete ATT before.

**On Examination:** Vital parameters normal limits, BP 120/80 mm Hg. He had a tender, right parasternal soft tissue chest swelling. Systemic examination revealed few coarse rales bilaterally with reduced breath sounds in the right infra axillary and infrascapular areas.

**Investigations:** Hb: 12. 6g/dl, TC : 12,290/C.mm, ESR: 50 mm/hr, FBS; 151 mg/dl, PPBS: 267mg/dL, S.IgE- 525Ing/ml, ECG - normal range, sputum AFB and HIV- negative, X- ray chest and CT chest showed a right upper lobe cavitary lesion, bilateral central bronchiectasis, right loculated pleural effusion and right chest wall abscess (Fig. 1). CT guided aspirate from the abscess site was negative for AFB by smear and culture. Bacterial culture and cytology were also negative. Fungal culture demonstrated presence of aspergillus fumigatus.

**DISCUSSION:** The risk factors for invasive pulmonary aspergillosis are prolonged neutropenia, neutrophil dysfunction (Chronic granulomatous disease), corticosteroid therapy, transplantation, haematologic malignancy, cytotoxic therapy and AIDS. Our patient had only diabetes mellitus which was detected during hospital stay and none of the predisposing factors as cited earlier. Chest wall aspergillosis with associated pleural effusion has been rarely described.<sup>2</sup>

Treatment recommended for invasive aspergillosis is usually amphotericin B or the more recent voriconazole. Due to financial constraints, our patient was treated with itraconazole and fortunately showed good clinical response. Pleural fluid analysis could not be done in view of minimal effusion that cleared with antifungal therapy.

Alternate and common diseases including tuberculous, nocardiosis and actinomycosis were ruled out initially and on follow up. The diagnosis of aspergillosis is made best by demonstrating the presence of septate, acute branching hyphae in the sample along with a culture that is positive for aspergillus species.

Therapy with antifungal can be curative. In conclusion, invasive aspergillosis should be considered in any patient with pleuroparenchymal and chest wall involvement. We wish to highlight the importance of obtaining early tissue samples because such clinicoradiological pattern may be misdiagnosed as tuberculosis in India.

**REFERENCES:**

1. Jyotikumar, Ashu Seith, Atin Kumar. Chest wall and mediastinal nodal aspergillosis in an immune- competent host. Diagnostic and interventional Radiology: 2009; 15: 176 – 178.
2. Vagal, Achala S, Staines. Sandra. Semi invasive aspergillosis with chest wall and spinal involvement. A case report and discussion. Infectious diseases in Clinical Practice, 2006: (6) 369- 372.

Financial or Other, Competing Interest: None.

Submission 22-10-2015, Peer Review 23-10-2015,

Acceptance 30-10-2015, Published 11-11-2015.

Corresponding Author:

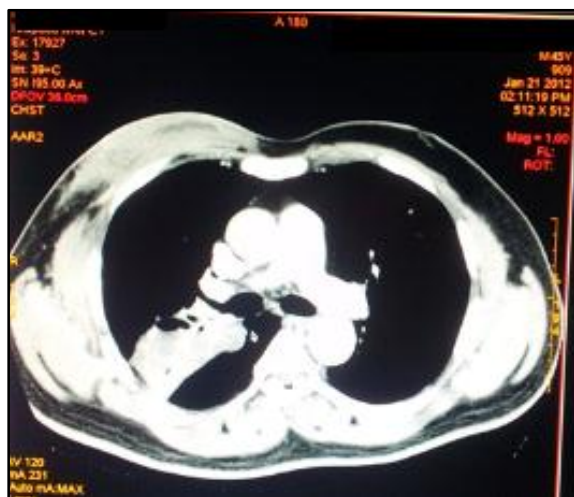
Dr. Supriya Adiody,

Pozhath House, Po: Kuriachira, Via: Anchery,

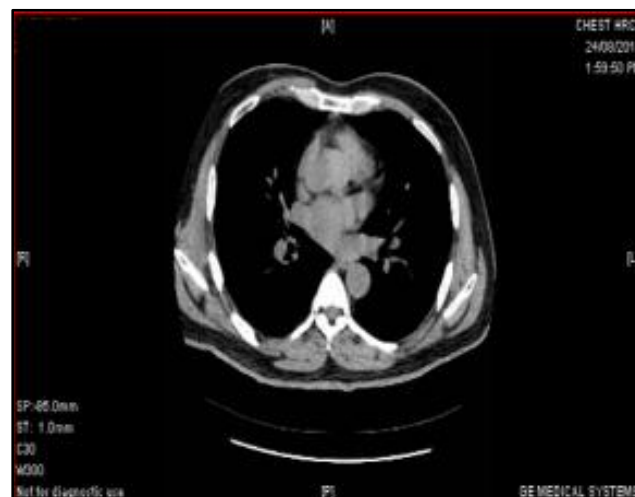T. T. Road, Thrissur-6, Kerala.

E-mail: supriyaadiody@yahoo.in

DOI:10.14260/jemds/2015/2263.



**Fig. 1: Showing Rt. Chest wall abscess**



**Fig. 2: Showing resolution of the chest wall abscess after treatment**